

Structural and white matter changes in patients with dementia: comparative FDG-PET and MRI studies

E. G. Steffensen¹, V. Prakash², S. F. Eskildsen³, K. Vestergård⁴, V. V. Iyer², and E.-M. Larsson⁵

¹Department of Radiology, Aalborg Hospital/Århus University Hospital, Aalborg, Denmark, ²Department of Nuclear Medicine, Aalborg Hospital/Århus University Hospital, Aalborg, Denmark, ³Department of Health Science and Technology, Aalborg University, Aalborg, Denmark, ⁴Department of Neurology, Aalborg Hospital/Århus University Hospital, Aalborg, Denmark, ⁵Department of Radiology, Uppsala University Hospital, Uppsala, Sweden

Introduction: In dementia imaging, MRI can provide not only morphological but also pathophysiological PET-like information. Furthermore, different biomarkers assessed by MRI have been successfully shown to differentiate dementia patients from the healthy controls. Cortical and/or hippocampal volumetry and evaluation of white matter (WM) damage may be used to support the diagnosis and characterization of dementia and are of special interest for the detection of changes in the early stages of the disease. However, despite intensive research, the question what is the best biomarker for classification of dementia is still open.

Purpose: To investigate whether one of the biomarkers assessed by MRI: cortical and hippocampal volumetry; changes in myoinositol (mI) and N-acetylaspartate (NAA) concentration in WM or fractional anisotropy (FA) and apparent diffusion coefficients (ADC) in tracts of cingulum and corpus callosum is preferable and can improve the diagnostic evaluation in dementia.

Material and method: Retrospective study of 34 patients with suspected early dementia or dementia of unclear type investigated with an advanced 3T MRI (Signa HDx, GE Healthcare) protocol which includes: high resolution 3D T1-weighted sequence; single voxel ¹H-spectroscopy in posterior cingulate cortex (PCC) and parietal WM and DTI sequence used for tractography. Twenty of the patients have also undergone ¹⁸F-DG PET (PET-CT, Discovery, GE Healthcare) examination: 9 were diagnosed as suspected fronto temporal dementia (FTD); 9 as suspected Alzheimer disease (AD), 2 had a normal PET.

Cortical thickness was calculated using Fast Accurate Cortex Extraction algorithm (1). Borders of the left and right hippocampi were outlined manually. Spectra were post-processed with LCModel package and ratio mI to NAA was calculated. Tractography was performed using DiffusionToolkit and TrackVis software (www.trackvis.org) and values of whole tract FA and ADC were measured for the left and right cingulum and corpus callosum.

Results: Table 1 presents a short summary of the parameters investigated divided in FDT(PET) and AD(PET) groups according diagnoses suggested by PET. Slightly lower right hippocampal volume and thinner cortex in posterior cingulate region and parietal lobes was observed for the group classified by PET as AD. Hippocampal atrophy was non-specific, whereas difference in thickness for PCC and parietal lobes was statistically confirmed (fig. 1). Higher ratio of mI/NAA was seen in AD patients ($p < 0.05$ for PCC). FA values were lower and ADC values higher in FTD group in comparison with AD. Combination of spectroscopy and DTI improves the discrimination between FTD and AD (Fig. 2).

Conclusion: While structural changes in patients with dementia are robust criteria to support the dementia diagnosis, accurate measurements of cortex thickness in parietal lobes and investigation of white matter abnormalities have a greater potential to facilitate early diagnosis and classification of dementia. We also suggest that PCC may be chosen as a region of investigation for the patients with dementia.

	FTD(PET)	AD(PET)	ALL
VOLUME (cm³)	N = 9	N = 9	N = 34
Hippocampus left	2.3±0.8	2.3±0.6	2.5±0.6
Hippocampus right	3.0±0.5	2.6±0.6	2.8±0.5
THICKNESS (cm)	N = 9	N = 9	N = 18
Parietal lobe left	1.6±0.2*	1.4±0.1*	1.5±0.2
Parietal lobe right	1.6±0.2*	1.4±0.2*	1.5±0.2
PCC left	2.2±0.3*	1.4±0.3*	1.8±0.5
PCC right	1.9±0.5*	1.3±0.2*	1.6±0.5
mI/NAA RATIO	N = 8	N = 8	N = 32
Parietal WM	0.59±0.14	0.79±0.26	0.65±0.18
PCC	0.65±0.11*	0.74±0.04*	0.67±0.12
FA	N = 8	N = 7	N = 30
Cingulum left	0.41±0.03	0.43±0.02	0.42±0.04
Cingulum right	0.41±0.03	0.42±0.02	0.42±0.04
Corpus callosum	0.51±0.02	0.52±0.02	0.51±0.03
ADC (10⁻⁹ m²/s)	N = 8	N = 7	N = 30
Cingulum left	0.80±0.06	0.78±0.02	0.78±0.05
Cingulum right	0.78±0.05	0.75±0.03	0.77±0.05
Corpus callosum	0.87±0.06	0.84±0.04	0.85±0.07

Table 1. Mean values of MRI biomarkers ± SD. Asterisk (*) indicates statistically significant differences ($p < 0.05$) between groups diagnosed by PET as FTD and AD

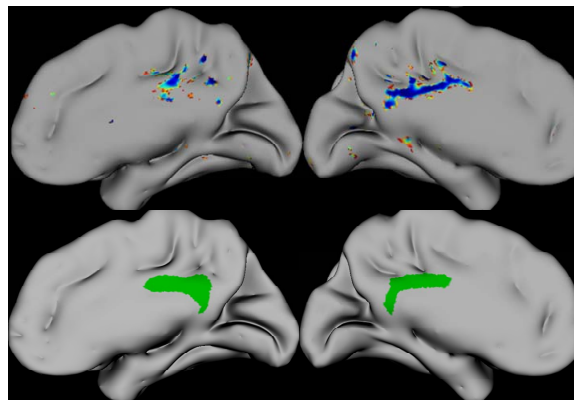


Fig. 1 Regions with reduced cortex thickness (blue colour) in patients with AD(PET) compared with FTD(PET) group ($p < 0.01$). Images below illustrate an averaged PCC region (green colour) for both group.

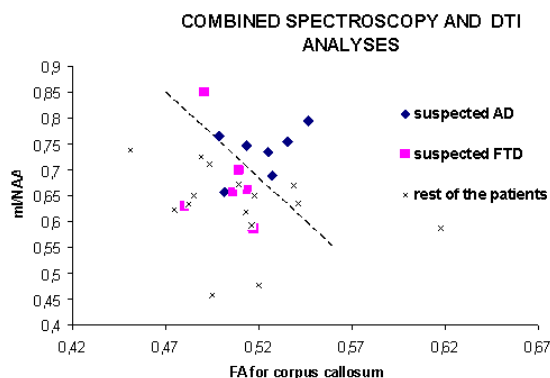


Fig. 2. FA values for corpus callosum tract plotted against mI/NAA ratio in PCC

References

- Eskildsen S.F. and Østergaard L.R. Active surface approach for extraction of the human cerebral cortex from MRI. 2006, 4191 LNCS-II, 823-830